



## Contribution of the Diode Laser in Implantology

Hajjaji S<sup>1\*</sup>, A.Esghir<sup>1</sup>, H.Hajjami<sup>1</sup>, A.Boughzella<sup>1</sup>

<sup>1</sup>Dental Medicine Department, Farhat Hached Hospital Tunisia

**ABSTRACT:** For the past fifteen years, lasers have been used successfully in dentistry. Each laser is specific by its wavelength. The absorption of laser radiation in hard or soft tissues depends on this wavelength. Laser-assisted dental surgery techniques have become recognized and must be part of our therapeutic arsenal. Their integration in implantology opens new possibilities. Among the lasers used in implantology is the diode laser which has interesting characteristics in the fields of decontamination and bio-stimulation, but can also be used for its ablative action on soft tissues. However, the success of an assisted laser treatment remains conditioned by the adequacy between the clinical case, the establishment of a good indication and the choice of the adapted laser material, which implies and requires a good knowledge by the practitioner of the respective modes of action of the laser, its main indications and its therapeutic limits.

**Keywords:** Diode laser, Implantology, Peri-implantitis, and wavelength.

### CASE REPORT

**\*Corresponding Author:**  
*Hajjaji S*  
Dental Medicine Department,  
Farhat Hached Hospital  
Tunisia

**How to cite this paper:**  
Hajjaji S *et al.*; "Contribution of the Diode Laser in Implantology". Middle East Res J. Dent., 2021 Nov-Dec 1(1): 1-5.

**Article History:**  
| Submit: 24.10.2021 |  
| Accepted: 27.11.2021 |  
| Published: 27.12.2021 |

**Copyright © 2021 The Author(s):** This is an open-access article distributed under the terms of the Creative Commons Attribution 4.0 International License (CC BY-NC 4.0) which permits unrestricted use, distribution, and reproduction in any medium for non-commercial use provided the original author and source are credited.

### INTRODUCTION

The laser or light amplification by stimulated emission of radiation was brought to light by Mr. Albert Einstein in 1917 when he published his work on the notions of absorption of light by matter. Then, it took almost half a century for its therapeutic applications to emerge with the appearance of the first ruby laser in 1960. Since then, the use of lasers in medical practice has increased.

Today, several types of medical lasers can be used. In odontology, four main lasers are most often used; namely the CO<sub>2</sub> laser, the diode laser, the erbium YAG laser and the He-NE laser.

In this article, we will focus on the diode laser. The objective was to answer a broad and complex question: is diode laser technology useful in implantology practice?

#### LASER DIODES OR SEMI CONDUCTORS (fig.1)

The appearance of these lasers dates from 1962 with the work of Holonyk-Basov-Townes. They convert electrical energy into light energy. They generally emit in the near infrared (between 800 and 1000 nanometers).

The laser beam is generated by a set of semiconductor elements called "laser diode array" which can be miniaturized to the extreme (10 mm or less). The power generated by these lasers varies in general from 4 Watts to 10 Watts or more, but a power beam can be combined by optical superposition of several beams giving very high powers (1000 Watts or more). These lasers have a very good tissue penetration up to 1300µm, an excellent absorption by hemoglobin, but also bacteria and melanin, with a very low absorption by water which explains its important penetration (about 5mm) (fig.2).

Diode lasers have variable wavelengths (fig.3) allowing them to be well used in soft tissue therapy (surgery and germ reduction).

#### CLINICAL APPLICATIONS OF DIODE LASERS IN IMPLANTOLOGY

##### Case report: Treatment of peri-implantitis

The Diode laser with a wavelength of 980 nm has interesting characteristics in the fields of decontamination and bio stimulation. The case report below shows the contribution of this laser in the treatment of peri-implantitis.

Mrs. R, 44 years old, presented with pain at the site of 14 and 15, restored with two implant-supported prostheses. Clinical examination showed inflammation

of the peri-implant mucosa, bleeding on probing, and suppuration draining from the peri-implant space (**fig4.a**). Radiological examination (**fig4.b**) shows bone loss around both implants.

The diagnosis is in favor of a peri-implantitis. The proposed course of action is a dynamic phototherapy which allows assisted laser decontamination by applying the Hydrogen Peroxide - Diode Laser protocol. The principle is to apply 10 volumes of peroxide and irradiate with the diode laser. The impact of the laser radiation on the oxygenated tissues allows the release of singlet oxygen, a reactive derivative of oxygen, which has a decontaminating effect.

Under local anesthesia, the pockets around the implants are realized with a periodontal probe. An incision is then made with a scalpel, and a mechanical debridement of the lesion is performed (**fig.5a and 5b**).

Then, the lesion is irrigated with a 10 volume hydrogen peroxide solution, without any pressure, left in situ for 2 to 3 minutes (**fig.6**). The laser is then adjusted (**fig.7**), and after validation, the laser fiber is introduced at the bottom of the lesion in a H<sub>2</sub> O<sub>2</sub> bath (**fig.8**). Pressing the pedal, then, triggers a series of laser shots in bursts. The 300 micron fiber must be in motion in the well irrigated lesion. The shots are interspersed with rest phases to give the tissues time to recover and

thus avoid overheating which is harmful to tissue regeneration. The diameter of the fiber is 320 microns and the power position is G-; that is to say 30 pulses per second of 150 microseconds at an average power of 5 watts.

Very fine curettes are sometimes used to eliminate the granulation tissue non-volitized by the laser action. The treatment is completed with the appearance of a dark red color indicating oxygenated blood.

Several sessions according to the same principle are necessary every 20 days to obtain the stabilization of the lesion (average of one application every 20 days during 3 months).

Finally, it should be noted that in our case, we used 3 effects of laser radiation:

- Decontamination effect obtained on previously oxygenated target tissues thanks to a photodynamic effect that is extremely effective on any dental or periodontal infection.
- Thermal effect but exclusively vasodilatation to allow a blood flow favorable for the healing of the surgical site.
- Bio-stimulant effect to accelerate bone and gum healing.



**Fig-1: Example of diode lasers**

Laser type	Construction	Wavelength(s)	Delivery system(s)
Argon	Gas laser	488, 515nm	Optical fibre
KTP	Solid state	532nm	Optical fibre
Helium-neon	Gas laser	633nm	Optical fibre
Diode	Semiconductor	635, 670, 810, 830, 980nm	Optical fibre
Nd:YAG	Solid state	1064nm	Optical fibre
Er,Cr:YSGG	Solid state	2780nm	Optical fibre
Er:YAG	Solid state	2940nm	Optical fibre, waveguide, articulated arm
CO <sub>2</sub>	Gas laser	9600, 10600nm	Waveguide, articulated arm

Fig-2: Different wavelengths of the diode laser

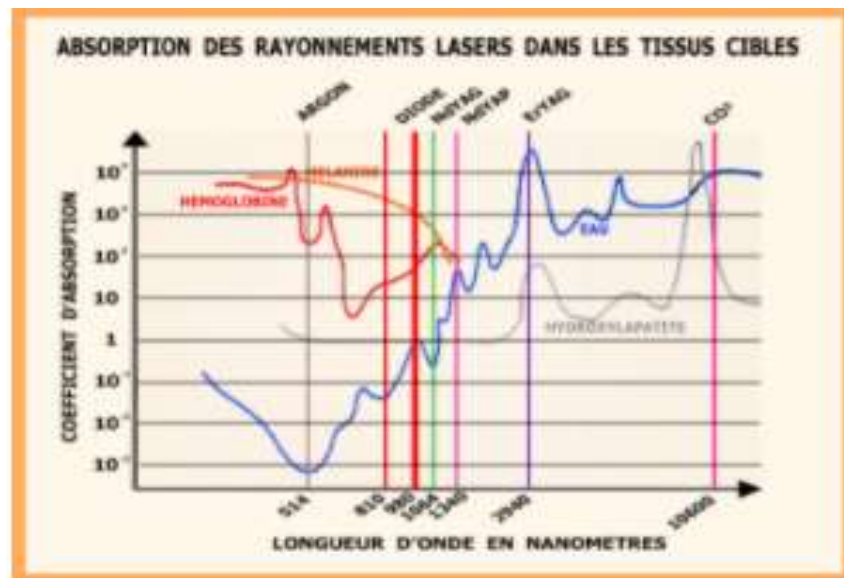


Fig-3: Tissue absorption of laser radiation (including diode laser)

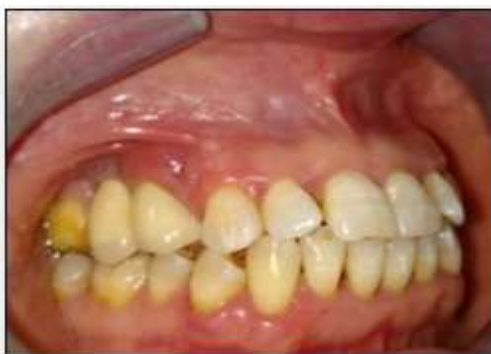

Fig-4.a: Clinical manifestations of tissue inflammation in relation to the 14 and 15.

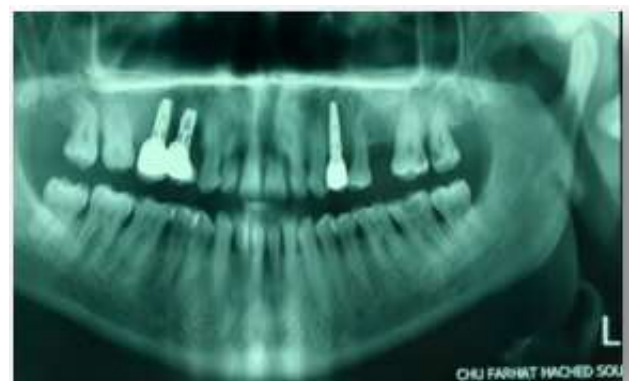
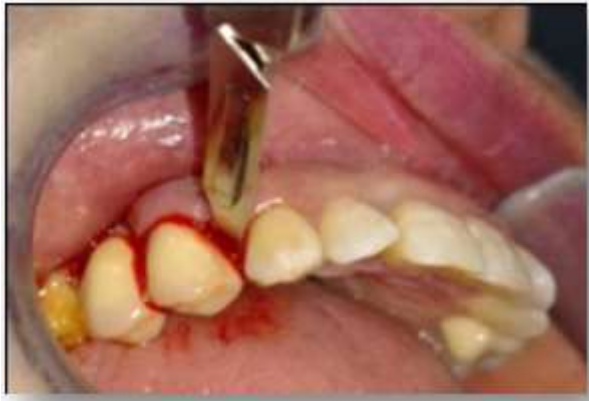
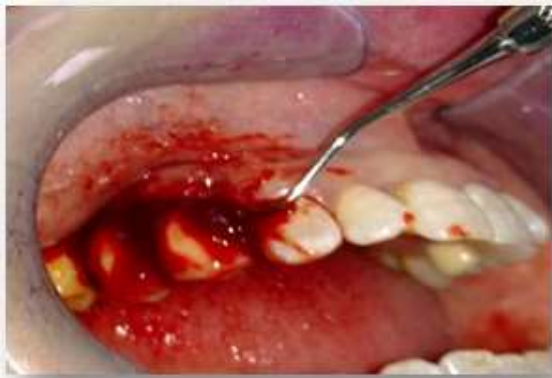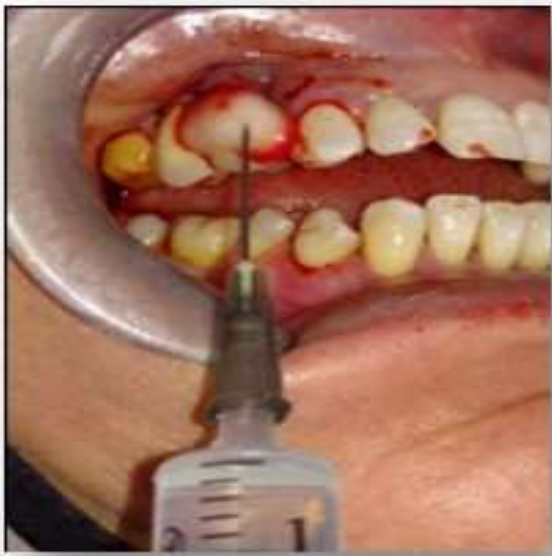Fig-4.b: Bone lysis around the two implants



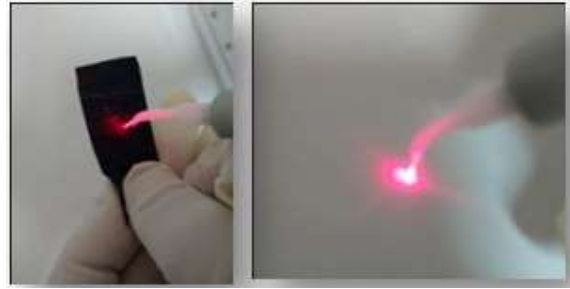
**Fig-5.a:** Incision of the lesion with a scalpel



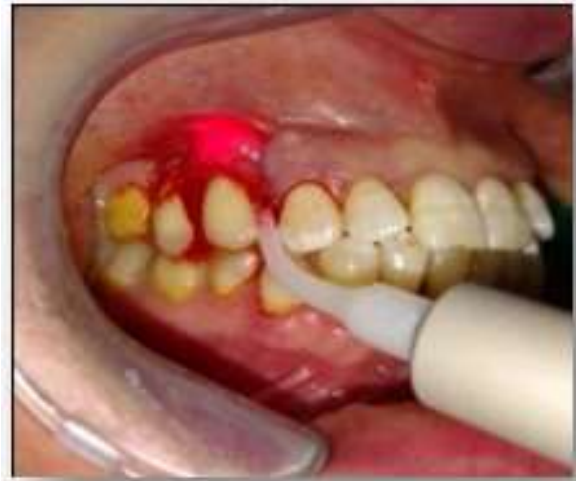**Fig-5.b:** Mechanical debridement of the lesion with a curette



**Fig-6:** Application of H2O2 (leave for 2 to 3 min)



**Fig-7:** Activation of the fiber and power adjustment



**Fig-8:** Laser application

## CONCLUSION

Lasers have become an indispensable therapeutic aid, both in general practice and in specialties. Their innumerable qualities place them at the forefront of useful professional investments. Diode lasers have very interesting properties in the field of implantology (decontamination, biostimulation, etc.)

However, it must be kept in mind that these laser techniques are only complementary techniques and that they must be part of a global treatment plan. Their effectiveness is closely linked to strict compliance with the protocols for their use, which can be mastered through quality training.

## REFERENCES

1. Rey, G. (2000). L'apport du laser dans le traitement des poches paradontales. *Implantodontie*, 38, 27-34.
2. COBB, C. (2006). Laser in periodontics: A review of literature. *J. Periodontal*, 77(4); 545-64 Review
3. Grunder, U. (2011). Crestal ridge width changes when placing implants at the time of tooth extraction with and without soft tissue augmentation after a healing period of 6 months: report of 24 consecutive cases. *International*

*Journal of Periodontics and Restorative Dentistry*, 31(1), 9.

4. Curti, M., Rocca, J. P., & Suermondt, A. B. C. (2001, April). SEM study of root canal walls lased with argon. In *Lasers in Dentistry VII* (Vol. 4249, pp. 8-14). International Society for Optics and Photonics.
5. Missika, P., Rey, G., Stroumza, J.M., Collection, J.P.I.O. (2010). Les lasers et la chirurgie dentaire .Chapitre 3: place réelle du laser en omnipratique quotidienne. Chapitre 6 : Intérêt du laser dans le traitement de la péri-implantite.
6. Rey, G., Missika, P. (2010). Traitements parodontaux et lasers en omnipratique dentaire. Masson
7. Rey, G. (2009). Efficacité des lasers en parodontologie. *La lettre de la stomatologie*, 43; 4-21.
8. REY, G., MISSIKA, P, et col. (2010). Les lasers et la Chirurgie dentaire; Ed CdP col JPIO
9. Rey, G. (2001). L'apport du laser dans les parodontites et les péri-implantites. *La lettre de la stomatologie*, 6-9.
10. John, G., Becker, J., Schmucker, A., & Schwarz, F. (2017). Non-surgical treatment of peri-implant mucositis and peri-implantitis at two-piece zirconium implants: A clinical follow-up observation after up to 3 years. *Journal of clinical periodontology*, 44(7), 756-761.
11. Schwarz, F., John, G., Schmucker, A., Sahm, N., & Becker, J. (2017). Combined surgical therapy of advanced peri-implantitis evaluating two methods of surface decontamination: A 7-year follow-up observation. *Journal of clinical periodontology*, 44(3), 337-342.
12. Caccianiga, G., Rey, G., Baldoni, M., & Pausco, A. (2016). Clinical, radiographic and microbiological evaluation of high level laser therapy, a new photodynamic therapy protocol, in peri-implantitis treatment; a pilot experience. *BioMed research international*.
13. Kaur, M., Sharma, Y. P. D., Singh, P., Sharma, S., & Wahi, A. (2018). Comparative evaluation of efficacy and soft tissue wound healing using diode laser (810 nm) versus conventional scalpel technique for second-stage implant surgery. *Journal of Indian Society of Periodontology*, 22(3), 228.
14. Walsh, L. J. « Low Level Laser Therapy », 16
15. Rocca, J.P., Augros, C., Bertrand-Flamand, C., M.F, E.T. (2008). Bertrand, Les lasers en odontologie. Paris, France: Éd. CdP, Impr.
16. Rey, G., Missika, P., Bufflier, P., Costesque, M., Rocca, J.P. (2010). Les lasers et la chirurgie dentaire: innovations et stratégies cliniques. Rueil-Malmaison, France: Éditions CdP.