

## Severe Head Injury with Blunt Paunch Force Trauma: A Case Report

Ahmad Reza Shahraki<sup>1\*</sup>

<sup>1</sup>General Surgeon, Assistant Professor, Department of Surgery, Zahedan Medical Faculty Zahedan University of Medical Sciences and Health Services, Zahedan, Iran

<p><b>Abstract:</b> A brain hemorrhage can occur in any part of the brain, can be caused by various conditions, both traumatic and non-traumatic. Nowadays, more and more teenagers are engaging in riskier sports either at school or in recreational settings. They are thus exposed to a variety of injuries including bruising or skull fractures. We report a case was a teenager 15 years' old that punched in a battle 1 hours ago and her friend bring him to hospital because of head swelling, that remains brain hematoma and Pneumocephalus for him. In head injuries caused by blunt trauma can also cause subarachnoid hemorrhage and subdural hemorrhage due to rupture of the superior cerebral vein and "bridging vein" due to pressure/trauma it can cause death, to distinguish subarachnoid hemorrhage from subdural hemorrhage needs to be done sprinkling with water. Traumatic brain injury is a common condition in the emergency services, affecting the pediatric and adult population significantly. Patterns of head injury as well as management principles in children are important differences compared to adults. The care of severe traumatic brain injuries is challenging and dynamic. Fortunately, with regard to the now established diagnosis of persistent TBI– Concussion, the patient now has a new treatment plan. Motor vehicle accidents are a common cause of traumatic brain injury, muscle, Spine and nerve injury. In recent years public awareness of the potential long-term effects of concussions and mild traumatic brain injuries sustained in sport of football has increased.</p>	<p><b>Case Report</b></p>
	<p><b>*Corresponding Author:</b>  <i>Ahmad Reza Shahraki</i>                      General Surgeon, Assistant Professor, Department of Surgery, Zahedan Medical Faculty, Zahedan University of Medical Sciences, Zahedan, Iran</p>
	<p><b>How to cite this paper:</b>                      Ahmad Reza Shahraki (2024). Severe Head Injury with Blunt Paunch Force Trauma: A Case Report. <i>Middle East Res J. Case Rep.</i> 4(3): 18-22.</p>
	<p><b>Article History:</b>                        Submit: 11.05.2024                          Accepted: 12.06.2024                          Published: 16.06.2024  </p>
<p><b>Keywords:</b> Skull Fracture, Brain Hematoma, Pneumocephalus. TBI, Trauma.</p>	
<p><b>Copyright © 2024 The Author(s):</b> This is an open-access article distributed under the terms of the Creative Commons Attribution <b>4.0 International License (CC BY-NC 4.0)</b> which permits unrestricted use, distribution, and reproduction in any medium for non-commercial use provided the original author and source are credited.</p>	

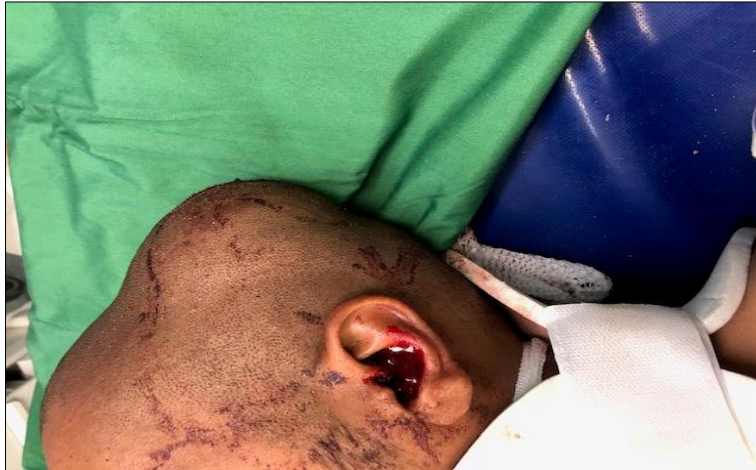### BACKGROUND

A brain hemorrhage can occur in any part of the brain, can be caused by various conditions, both traumatic and non-traumatic. According to the 2014 Surveillance Report of Traumatic Brain Injury, in the United States, there are approximately 2.87 million head injury patients [1]. Nowadays, more and more teenagers are engaging in riskier sports either at school or in recreational settings. They are thus exposed to a variety of injuries including bruising or skull fractures [2]. Teenager exposed to a variety of injuries including bruising or skull fractures. Their delving into sports originally thought to be exclusively preserves for adults, but by commission, they were exposed to corresponding head injuries of adult sports. Typical examples are karting, horse riding, skiing, boxing, and cycling. This is more common among teens in the Western World [3]. The aim of this case presentation is showing horrible

results of unsafe activities. Traumatic brain injury is a common condition in the emergency services, affecting the pediatric and adult population significantly. Patterns of head injury as well as management principles in children are important differences compared to adults. The aim of this paper is this factor in multiple trauma that do not miss and in easy way can be missed and have horrible side effects on patient, family and health system to involve in caring and results.

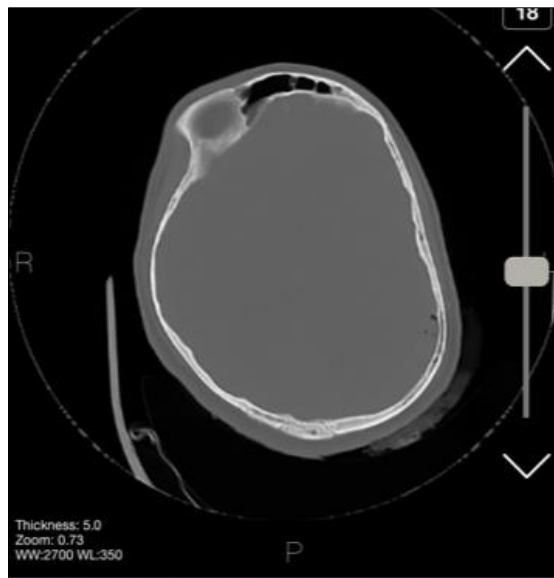
### CASE PRESENTATION

Our case was a teenager 15 years' old that punched in a battle 1 hours ago and her friend bring him to hospital because of head swelling. His GCS at first was 13 and blood pressure was 110/60 and heart rate was 96. and his friend gave us a history of street battle between teenagers.

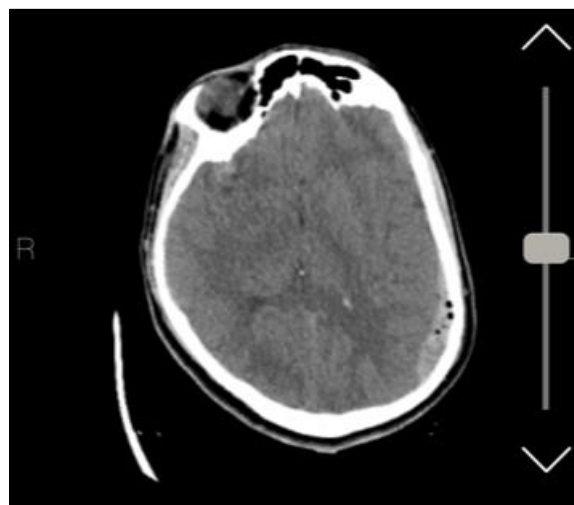


**Figure 1: First exam of patient**

We start the examination and did chest x-rays and FAST for him those were normal and we send her to do brain CT:



**Figure 2: Pneumocephalus was see**



**Figure 3: Pneumocephalus and brain hematoma was seen**

He was rescued and underwent of craniotomy and after medication he discharged healthy and successfully.

## CONCLUSION

Epidemiologically, nowadays teenagers and young people are more regularly engaged in games and recreational sports in schools. Some of these games are more accident-prone than others [2]. Karting is one of the sports that causes head injuries. In a study of 68 cases of craniofacial trauma in the sport [3]. The study of trauma caused by boxing was carried out by Potter, They showed an incidence of 12.7% for every 1000 participants. Head and neck (22.5%) are the most affected areas after the hand (33%) [4]. In Moroder [5], study, lesions of the skull and shoulder (21.2% for each site) came 3rd in position after those of back (30.3%), knee (24.2%) [6]. have noted the effectiveness of helmets in reducing head injuries among helmeted skiers at 5.3% against 36.8% compared to non- helmeted in 57 children. Throwing sports (javelin, discus, shot, hammer) involves the use of heavy, blunt or sharp objects [7]. Clinically and therapeutically, penetration of skull ping-pong ball like the one in our study is rare in teenagers and adolescents. They are more frequent in newborn babies with the utility of an instrumental delivery (forceps, spatula or digital printing hand of the obstetrician). Simplicity of the surgical procedure and the risk of developing compression callus underlie decidedly surgical attitude being widely shared [8].

In cases of head injury due to blunt trauma, blood infiltration will be found in the layers of the scalp and muscles in the direction of the trauma. The presence of blood infiltration is an intravital sign of evidence of extravasation of blood cells in the tissue. Another finding may be a skull base fracture in the posterior fossa caused by a direct blow to the occipital region. At the base of the skull, a fracture in the posterior fossa can cause symptoms such as bleeding from the nose, mouth, and ears, damage to the cranial nerves and cause raccoon eyes. In head injuries caused by blunt trauma can also cause subarachnoid hemorrhage and subdural hemorrhage due to rupture of the superior cerebral vein and “bridging vein” due to pressure/trauma it can cause death, to distinguish subarachnoid hemorrhage from subdural hemorrhage needs to be done sprinkling with water [1]. Clinically and therapeutically, penetration of skull ping-pong ball like the one in our study is rare in teenagers and adolescents. They are more frequent in newborn babies with the utility of an instrumental delivery (forceps, spatula or digital printing hand of the obstetrician). Simplicity of the surgical procedure and the risk of developing compression callus underlie decidedly surgical attitude being widely shared [8]. The care of severe traumatic brain injuries is challenging and dynamic [9]. Human injury resulting from encounters with non-domesticated animals is an increasing situation throughout the world [10]. Traumatic brain injury is a

common condition in the emergency services, affecting the pediatric and adult population significantly [11]. The management of patients presenting with poly-trauma is continuous, dynamic and extremely challenging in terms of the staff involved, the multidisciplinary team that will monitor the patient’s progress [12]. The care of severe traumatic brain injuries is challenging and dynamic. This case highlights the unexpected recovery of a patient and serves as a reminder that there is variability among patients [13], Traumatic brain injury is a common condition in the emergency services, affecting the pediatric and adult population significantly [14]. For being an important cause of disability, TBI generates high costs to health care systems [15-17]. Geriatric patients with severe head injury are less likely than their younger counterparts to be transferred to neurosurgical trauma centers [18]. The care of severe traumatic brain injuries is challenging and dynamic [19]. Fortunately, with regard to the now established diagnosis of persistent TBI– Concussion, the patient now has a new treatment plan (20).

### Assessment and Diagnosis [20]

Chronic Mild to Moderate Traumatic Brain Injury–Concussive Type with Persistent Cognitive Deficits and Balance Deficits and MRI Correlates per patient’s 2016 medical records.

### Plan

- i. Referred to Neurologist secondary to associated diagnosis of dizziness and associated balance deficits–positive Romberg test and positive Tandem Walk test.
- ii. Referred to Physical and Occupational Therapy for Vestibular Dysfunction Therapy secondary to associated diagnoses of persistent dizziness and balance deficits including a positive Romberg test and positive Tandem Walk test.
- iii. Referred to Neuropsychologist for Cognitive Testing secondary to associated diagnosis of TBI– Concussion and numerous persistent related signs and symptoms of impaired cognition.
- iv. Referred to Integrative Cognitive Rehabilitation Program secondary to associated diagnosis of TBI– Concussion and persistent related signs and symptoms of impaired cognition.

Motor vehicle accidents are a common cause of traumatic brain injury, muscle, spine and nerve injury [21, 22].

In recent years public awareness of the potential long-term effects of concussions and mild traumatic brain injuries sustained in sport of football has increased [23].

### Declarations:

### Ethical Approval and Consent to Participate:

The content of this manuscript are in accordance with the declaration of Helsinki for Ethics. No committee approval was required. Oral and written consent to participate was granted by the parents.

#### Consent for Publication:

“Written informed consent was obtained from the patient's legal guardian for publication of this case report and any accompanying images. A copy of the written consent is available for review by the Editor-in-Chief of this journal.”

**Availability of Supporting Data:** It is available.

**Competing Interests:** The author declares that they have no competing financial interests and nothing to disclose.

**Funding:** There is no funding.

#### Authors' Contributions:

Ahmad Reza Shahraki is the surgeon of patient and writes this paper.

The author declares that they have no competing financial interests and nothing to disclose.

#### ACKNOWLEDGEMENTS

In head injuries caused by blunt trauma can also cause subarachnoid hemorrhage and subdural hemorrhage due to rupture of the superior cerebral vein and “bridging vein” due to pressure/trauma it can cause death, to distinguish subarachnoid hemorrhage from subdural hemorrhage needs to be done sprinkling with water.

#### REFERENCES

- Purwanti, T., Erfan Kusuma, M. S., & Yudianto, A. (2022). Head injury case with blunt force traumatic: Case report. *The New Armenian Medical Journal*, 16(1), Address for Correspondence: 109-116.
- Ibrahima, F., & Motah, M. (2015). Depressed skull fracture by a mass of 3 kg in shot putt an adolescent of 13 years. A rare sports injury. A rare fracture of the skull-deflection shot putt. *International journal of surgery case reports*, 6, 203-205.
- Miller, B. L., Waller, J. L., & McKinnon, B. J. (2011). Craniofacial injuries due to golf cart trauma. *Otolaryngology--Head and Neck Surgery*, 144(6), 883-887.
- Potter, M. R., Snyder, A. J., & Smith, G. A. (2011). Boxing injuries presenting to US emergency departments, 1990–2008. *American journal of preventive medicine*, 40(4), 462-467.
- Moroder, P., Runer, A., Hoffelner, T., Frick, N., Resch, H., & Tauber, M. (2011). A prospective study of snowkiting injuries. *The American Journal of Sports Medicine*, 39(7), 1534-1540.
- Rughani, A. I., Lin, C. T., Ares, W. J., Cushing, D. A., Horgan, M. A., Tranmer, B. I., ... & Florman, J. E. (2011). Helmet use and reduction in skull fractures in skiers and snowboarders admitted to the hospital. *Journal of Neurosurgery: Pediatrics*, 7(3), 268-271.
- Pendergraph, B., Ko, B., Zamora, J., & Bass, E. (2005). Medical coverage for track and field events. *Current sports medicine reports*, 4(3), 150-153.
- Palchak, M. J., Holmes, J. F., Vance, C. W., Gelber, R. E., Schauer, B. A., Harrison, M. J., ... & Kuppermann, N. (2004). Does an isolated history of loss of consciousness or amnesia predict brain injuries in children after blunt head trauma?. *Pediatrics*, 113(6), e507-e513.
- Nelson, C. G., Elta, T., Bannister, J., Dzandu, J., Mangram, A., & Zach, V. (2016). Severe traumatic brain injury: A case report. *The American journal of case reports*, 17, 186.
- Mitchell, K. B., Kotecha, V. R., & Chandika, A. (2011). Bush animal attacks: management of complex injuries in a resource-limited setting. *World journal of emergency surgery*, 6, 1-4.
- Alvis-Miranda, H. R., Castellar-Leones, S. M., Velásquez-Loperena, D. D., Villa-Delgado, R., Alcalá-Cerra, G., & Moscote-Salazar, L. R. (2013). Traumatic brain injury due to bull assault in a girl: a case report. *Maedica*, 8(4), 377.
- Liliana, D., Virginia, M., & Mihaela, A. (2021). Case of severe head trauma caused by a car accident. *International Journal of Case Reports*, 5, 220. DOI: 10.28933/ijcr-2021-05-2905.
- Nelson, C. G., Elta, T., Bannister, J., Dzandu, J., Mangram, A., & Zach, V. (2016). Severe traumatic brain injury: A case report. *The American journal of case reports*, 17, 186.
- Alvis-Miranda, H. R., Castellar-Leones, S. M., Velásquez-Loperena, D. D., Villa-Delgado, R., Alcalá-Cerra, G., & Moscote-Salazar, L. R. (2013). Traumatic brain injury due to bull assault in a girl: a case report. *Maedica*, 8(4), 377.
- Choi, B. Y., Jang, B. G., Kim, J. H., Lee, B. E., Sohn, M., Song, H. K., & Suh, S. W. (2012). Prevention of traumatic brain injury-induced neuronal death by inhibition of NADPH oxidase activation. *Brain research*, 1481, 49-58.
- Engel, D. C., Mikocka-Walus, A., Cameron, P. A., & Maegele, M. (2010). Pre-hospital and in-hospital parameters and outcomes in patients with traumatic brain injury: a comparison between German and Australian trauma registries. *Injury*, 41(9), 901-906.
- Arango-Lasprilla, J. C., Ketchum, J. M., Cifu, D., Hammond, F., Castillo, C., Nicholls, E., ... & Deng, X. (2010). Predictors of extended rehabilitation length of stay after traumatic brain injury. *Archives of physical medicine and rehabilitation*, 91(10), 1495-1504.

18. Ross, A. G. (2014). Prudent care of head trauma in the elderly: a case report. *Journal of Medical Case Reports*, 8, 1-3.
19. Clinton, G., Nelson, T. E., Jeanette, B., James, D., Alicia, M., & Victor, Z. (2016). Unusual clinical course, Management of emergency care, Educational Purpose (only if useful for a systematic review or synthesis). DOI: 10.12659/AJCR.897116. *Am J Case Rep*, 17, 186-191.
20. Jones, P. M., Brown, T. L., & Bentley, R. (2016). Traumatic brain injury-missed diagnosis: a case report. *MOI Clin Med Case Rep*, 4(4), 101-104.
21. Peeters, W., van den Brande, R., Polinder, S., Brazinova, A., Steyerberg, E. W., Lingsma, H. F., & Maas, A. I. (2015). Epidemiology of traumatic brain injury in Europe. *Acta neurochirurgica*, 157, 1683-1696.
22. Langlois, J. A., RutlandBrown, W., & Thomas, K. E. (2004). Traumatic brain injury in the United States: Emergency department visits, hospitalizations, and deaths. CDC. 2004.
23. Pandey, K. (2022). Cases of head injuries in football sport: A case study of Ghaziabad District, Uttar Pradesh. *Journal of Family Medicine and Primary Care*, 11(11), 6697-6703.