

Neuraxial Anaesthesia in a Patient with Charcot-Marie-Tooth Disease and Hip Fracture- A Case Report and Literature Review

Mayet A^{1*}, Tayob YN^{1*}, Moodley A¹, Elghobashy A¹

¹University of the Witwatersrand, Department of Anaesthesia, Edenvale Regional Hospital, Johannesburg, South Africa

<p>Abstract: Encountering patients who present with rare conditions is daunting considering the scarcity of published recommendations. Charcot-Marie-Tooth (CMT) Disease is a rare neuromuscular disorder. We review a case of strongly suspected CMT disease in a patient presenting for hip surgery and assess the clinical course and successful treatment outcome following neuraxial anesthesia and sedation. Furthermore, literature is reviewed assessing the effects of the disease on various physiological systems during the peri-operative period.</p>	<p style="text-align: center;">Case Report</p>
	<p style="text-align: center;">*Corresponding Author: <i>Tayob YN</i> University of the Witwatersrand, Department of Anaesthesia, Edenvale Regional Hospital, Johannesburg, South Africa</p>
	<p style="text-align: center;">How to cite this paper: Mayet A <i>et al</i> (2024). Neuraxial Anaesthesia in a Patient with Charcot-Marie-Tooth Disease and Hip Fracture- A Case Report and Literature Review. <i>Middle East Res J. Case Rep</i>, 4(3): 23-26.</p>
<p>Keywords: Anaesthesia, Neuraxial Techniques, Charcot-Marie-Tooth Disease, Hereditary Motor and Sensory Neuropathy (HMSN).</p>	<p style="text-align: center;">Article History: Submit: 19.05.2024 Accepted: 21.06.2024 Published: 25.06.2024 </p>
<p>Copyright © 2024 The Author(s): This is an open-access article distributed under the terms of the Creative Commons Attribution 4.0 International License (CC BY-NC 4.0) which permits unrestricted use, distribution, and reproduction in any medium for non-commercial use provided the original author and source are credited.</p>	

INTRODUCTION

Charcot-Marie-Tooth Disease is a hereditary sensory and motor polyneuropathy with variable penetrance in patients. Patients typically have an insidious disease onset and by the 1st-3rd decade of life they may begin to have muscular weakness and atrophy of their distal muscles, particularly of the hands and feet. The disease is known by a variety of names including Hereditary Motor and Sensory Neuropathy, Dejerine-Sottas Disease and Roussy Levi Syndrome [1].

A lack of information surrounding the pathophysiology and treatment course of the disease exists, resulting in missed diagnosis, improper treatment and management of patients with CMT. It is one of the most prevalent inherited neurological disorders, affecting 126 000 people in the United States and 2.6 million people across the globe [2].

In terms of the pathophysiological process, more than 40 genes are found to be implicated in affecting the axon itself, the myelin sheath or both, resulting in an adolescent or adult-onset with a progressive disease pattern. Over half of all genetic alterations are secondary to a duplication of the peripheral myelin protein 22 (PMP22) gene on chromosome 17 [2].

The classification of CMT Disease was based upon nerve conduction velocities (NCV) in patients classifying them into CMTI, CMTII and Dominant Intermediate-CMT. Letters were added on to the classification to identify the involved gene [1]. There was a proposed revision of the classification system which proved to be more descriptive in terms of mode of inheritance, neuropathy and type of gene, encompassing all inherited neuropathies [1].

The most salient types of CMT have been classified by NCV, clinical features, histopathology and molecular genetics into types I-VI (see Table 1). From the spectrum of presentations, it may be inferred that anaesthetic impact is highly variable and management plans must be thoroughly individualized. Furthermore, literature examining the effect of anaesthesia on this group of disorders makes the narration of case reports and the anecdotal approaches undertaken in the clinical setting important. The patients' presentation and operative course is reviewed.

CASE REPORT

❖ Pre-Operative

• History

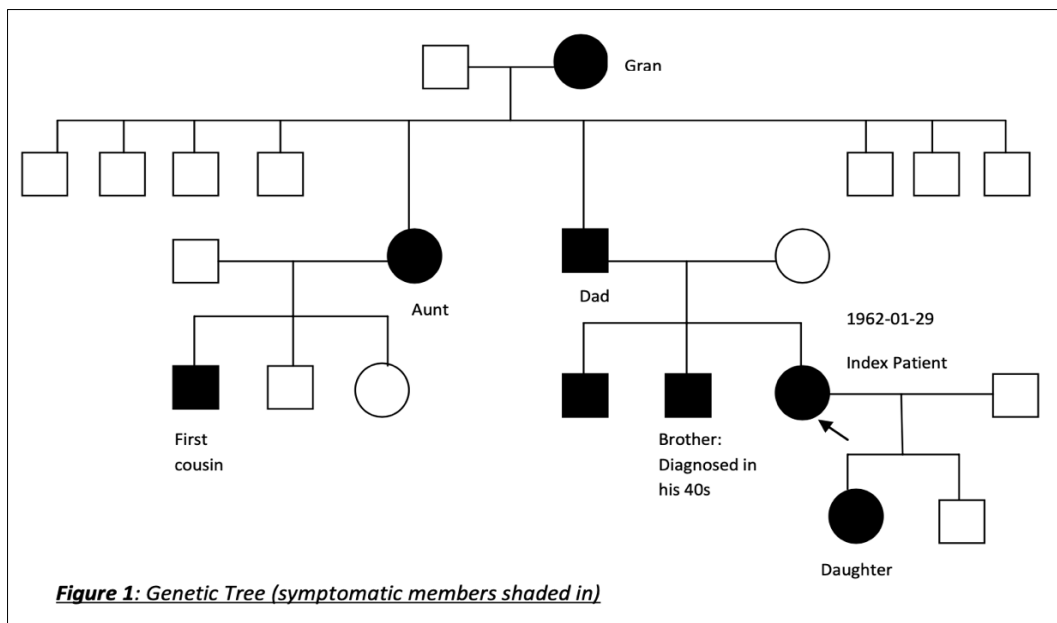
A 60-year-old female patient presented to the Accident and Emergency Department complaining of right groin pain following a fall on uneven ground the

day before admission. The fall had no association with loss of consciousness and no other injuries were sustained. X rays showed a right neck of femur fracture and osteopenia. No other joints were affected by the injury and all pulses were present.

The patient was a known hypertensive on treatment with amlodipine once daily and had completed isolation for a mild COVID-19 infection. She had three previous surgeries under general anesthesia which were uneventful. She is a smoker of 20 pack years but reported good pre-morbid effort tolerance without respiratory insufficiency. She reported difficulty with balance, causing frequent falls. No symptoms of visual or vocal changes, resting tremors, restless leg syndrome or

autonomic dysfunction were reported. The triad of positive symptoms (tingling), negative symptoms (numbness) and pain were felt in her lower limbs more than her upper limbs [3].

Her family history of CMT is supported by four generations of symptomatic members as shown in Figure 1. Her brother was given a formal diagnosis in his 40s based on plasma, electromyogram (EMG), biopsy and NCV testing. She reports having been unwilling to undergo the same battery of tests for herself. This makes the inheritance pattern difficult to elucidate since CMT may be asymptomatic in 25% of cases through variable penetrance [3].



• Preoperative Assessment

Preoperative assessment of the patient revealed that general examination, cardiovascular, and respiratory exams were within normal limits. Her airway was assessed as a Mallampati II, with normal cervical and temporomandibular range of motion, a normal thyromental and sternomental distance. The patient had hallmark features of hammertoes with bilateral high foot arches and hollowing of the interossei on the dorsal aspect of both feet with a lack of an “inverted champagne bottle” appearance of the legs. She did not have clawing or wasting of the thenar eminences or interossei of her hands with her handwriting remaining neat and legible. Her speech and respiration were normal. She did not display difficulty swallowing. She had a Glasgow Coma Scale (GCS) score of 15/15. Her right leg was not amenable to a comprehensive neurological exam on account of her fracture. Aside from this, she had normal tone globally, normal reflexes in her upper limbs but reduced reflexes of 1/4 in her left lower limb and reduced power of 4/5 in upper and lower limbs. Her temperature sensation was reduced globally.

⇒ Investigations

The patients’ electrocardiogram (ECG) showed normal sinus rhythm with a normal axis and a rate of 83bpm. The chest x-ray done on admission showed normal lung fields and a normal cardiothoracic ratio.

Pre-operative formal blood work trends in the ward showed possible pre-renal dysfunction with hyperkalaemia and hyponatraemia that was responsive to shifting and fluids, respectively. The use of Enalapril in the ward may also be a contributory factor. The improved potassium levels coupled with absence of ECG changes excluded the need for further active management of electrolytes in theatre.

The patient was counselled about the use of a neuraxial anaesthetic technique in the setting of CMT and informed consent was obtained.

❖ INTRA-OPERATIVE

• Management

The patient was managed using a neuraxial block with intrathecal injection of 3ml of 0.5% plain Bupivacaine and 0.4ml (20mcg) of fentanyl. Supplementation nasal prong oxygen was applied, and the patient was maintained at a Modified Ramsay Sedation Scale Score of 4-5 with Ketofol solution (1:3 dilution). Blood pressures were maintained with titrated phenylephrine and ephedrine boluses without the need for excessive use of these drugs. IV fluids administered included Ringers Lactate (total of 1500ml). The patient had a urine output of 300ml and an estimated blood loss of 500ml. Fifty micrograms Fentanyl and 1g Paracetamol were administered intravenously to ameliorate the postoperative analgesic course.

❖ Post-Operative

• Follow-up

The patient was stable postoperatively. She reported resolution of the spinal seven hours after administration. Further analgesic requirements were managed with oral paracetamol (1g QID), oral tramadol (50mg TDS) and intra-muscular pethidine 50mg as needed. Her neurological picture on examination was identical to her pre-operative assessment and no adverse reactions or side effects were reported. Patient was referred to physiotherapy for ambulation and rehabilitation.

DISCUSSION

Preoperatively, the clinician needs to differentiate the disease from muscular dystrophy and multiple sclerosis which have differing pathophysiology and different implications for anaesthetic management. CMT is distinguished by largely inherited (occasionally de novo) peripheral nerve involvement; muscular dystrophy is mostly characterised by inherited disorders of dystrophin at the level of the muscle [4]. More common causes of peripheral neuropathy should also be excluded viz: direct nerve trauma; metabolic causes including diabetes and vitamin B deficiency; paraneoplastic syndromes; infectious or inflammatory causes including HIV, syphilis, rheumatoid arthritis, leprosy and the effect of toxins and drugs including alcohol, solvents and heavy metals [3].

It is evident from the literature that meaningful appraisal would have to consider a multi-system approach to anaesthesia and CMT. These can be broadly divided into patient factors and anaesthetic factors.

Patient Factors

• Cardiovascular System

Abnormalities in CMT patients may include long QT syndrome, paroxysmal atrial flutter, cardiomyopathy and complete atrioventricular block [5].

• Respiratory System and Airway

CMT involvement of the Phrenic nerve may cause respiratory insufficiency of the diaphragm [6]. Lung function tests and arterial blood gas analysis may be necessary where clinically indicated to guide ventilation and the need for postoperative high dependency units. Non-invasive positive pressure ventilation is helpful when forced vital capacity is <50% predicted, nocturnal sleep desaturation <88% for >5 minutes, maximal expiratory pressure <60cmH₂O or an awake PaCO₂ of >45mmHg [5]. Advanced age and upper limb involvement should raise suspicions of respiratory insufficiency. Furthermore, vocal changes may indicate laryngeal dysfunction with an increased propensity for aspiration [6].

• Renal System

Sixteen cases were reported wherein a mutation in INF2 resulted in both CMT disease and Focal Segmental Glomerulosclerosis, which is a cause of renal insufficiency and nephrotic syndrome [7].

• Neurological System

Baseline visual ability needs to be established as changes have been observed in the thickness of the retinal nerve fibre layer, ganglion cell layer complex and visual evoked potential due to optic neuropathy [8]. This would help differentiate between pre-existing visual impairments or those caused due to intraoperative positioning or procedural injuries.

Autonomic dysfunction manifests as impaired temperature regulation with the absence of sweating in CMT patients [6]. Potential delayed gastric emptying should also be considered. A high prevalence (65.8%) of autonomic dysfunction especially in CMT IA in females above 60 years of age was reported. This resulted in greater rates of burning dysesthesias, cardiac defibrillator/pacemaker use and dependence on CPAP/BiPAP [9].

Anaesthetic Factors

• Induction Agents and Maintenance

Intravenous propofol and sevoflurane induction and maintenance were successfully used in two teenage boys with CMT [6]. A theoretical risk of neurotoxicity is also posed by nitrous oxide use since it inhibits methionine synthase [6].

• Muscle Relaxants and Reversal

Depolarising and non-depolarising muscle relaxants have been used successfully in mildly affected CMT patients, although the use of succinylcholine raises valid theoretical concerns in advanced disease with cholinergic receptor upregulation from chronic denervation and potential hyperkalaemia [6]. Succinylcholine and volatiles have also been postulated to cause malignant hyperthermia (MH) even though CMT is a peripheral neuromuscular disease. In practice

however, it was confirmed that the use of succinylcholine and volatile agents in 86 CMT patients was uneventful [6].

Mivacurium did not show prolongation of its duration of action in five CMT patients aged between 7 and 12 years old [6]. No reported change for rocuronium was noted [10].

The safe use of normal doses of glycopyrrolate and pyridostigmine has been reported, furthermore it is postulated that although sugammadex is safe in myasthenia gravis and Duchenne muscular dystrophy, it poses a risk of exacerbating QT prolongation and atrioventricular block in CMT patients [5].

• Analgesia

CMT patients may have baseline severe pain resulting in analgesic dependence [6]. This may pose a challenge to agents for musculoskeletal pain and tricyclic anti-depressants, carbamazepine or gabapentin for neuropathic pain [6].

• Local and Regional Anaesthesia

Pre-existing neurology is a controversial background for the use of local and regional approaches with abounding concerns of possible further deterioration. Bosenberg and Larken report the uneventful use of a peroneal block, saphenous block and a continuous popliteal peripheral nerve catheter kept in situ for 48 hours [6]. Ortiz et al further strengthen this stance in their report of the successful use of spinal anaesthesia for hip fracture in a CMT patient with co-existing chronic obstructive pulmonary disease, type II diabetes and previous pulmonary tuberculosis. They also draw attention to other obstetric and orthopaedic cases where spinal, caudal or epidural approaches were used effectively, albeit with some prolongation of the block and where brachial plexus blockade was used without worsening respiratory or neurological status [10].

CONCLUSION

This case has mirrored the smooth, uneventful course of neuraxial anaesthesia for CMT Disease in otherwise healthy patients described in corresponding international case reports. Where the disorder coexists with airway, respiratory, renal or other complexities, the anaesthetic approach should evolve accordingly.

It remains a hope that improved diagnostic rates would yield management protocols promulgated by more robust evidence-based medicine in the years to come.

ACKNOWLEDGEMENTS

The authors acknowledge the patient for consenting to the narration of the case for the benefit of medical science. All measures to preserve due confidentiality have been undertaken. We declare that there are no conflicts of interest or sponsorships affecting this report. This case report was published with the written consent of the patient.

REFERENCES

1. Bird TD. Charcot-Marie-Tooth Hereditary Neuropathy Overview. Gene Reviews [Internet]. 1998 Sep 28; Available from: <https://www.ncbi.nlm.nih.gov/books/NBK1358/>
2. Charcot-Marie-Tooth Disease | National Institute of Neurological Disorders and Stroke [Internet]. Available from: <https://www.ninds.nih.gov/health-information/disorders/charcot-marie-tooth-disease>
3. Alberts, N. W. (2008). *Engaging With Charcot-Marie-Tooth Disease: A Grounded Theory Approach*. [Internet]. [South Africa]: The University of South Africa; [cited 2022 Aug 22]. Available from: <https://core.ac.uk/download/pdf/43164833.pdf>
4. LaPelusa, A., Kentris, M. (2024). *Muscular Dystrophy*. In: StatPearls [Internet]. Treasure Island (FL): StatPearls Publishing; [cited 2024 Feb 19]. Available from: <http://www.ncbi.nlm.nih.gov/books/NBK560582/>
5. Kim, J. W., Kim, G., Kim, T. W., Han, W., Maeng, J. H., Jeong, C. Y., ... & Park, D. H. (2019). Anesthesia in a patient with Charcot-Marie-Tooth disease with pneumothorax: a case report. *Journal of International Medical Research*, 47(11), 5896-5902.
6. Bosenberg, A., & Larkin, K. (2006). Anaesthesia and Charcot-Marie-Tooth disease: Syndromic vignettes in anaesthesia. *Southern African Journal of Anaesthesia and Analgesia*, 12(4), 131-133.
7. Boyer, O., Nevo, F., Plaisier, E., Funalot, B., Gribouval, O., Benoit, G., ... & Mollet, G. (2011). INF2 mutations in Charcot-Marie-Tooth disease with glomerulopathy. *New England Journal of Medicine*, 365(25), 2377-2388.
8. Botsford, B., Vuong, L. N., Hedges III, T. R., & Mendoza-Santiesteban, C. E. (2017). Characterization of Charcot-Marie-Tooth optic neuropathy. *Journal of neurology*, 264, 2431-2435.
9. Ramchandren, S., & Tirella, C. (2018). Dysautonomia in Charcot-Marie-Tooth Disease and Correlations with Patient-Reported Disability (P2. 112).
10. Ortiz, E. R., Martínez, E., Martín, J., Maiza, L., & Medina, J. (2019). Spinal anesthesia in a patient with Charcot-Marie-Tooth disease undergoing orthopedic surgery: case report. *Colombian Journal of Anesthesiology*, 47(3), 180-183.